

FMF presented by aseptic abscesses

Aseptik apselerle tanı alan bir FMF olgusu

● Seyda Bilgin¹, ● Serdal Uğurlu²

¹Istanbul University-Cerrahpaşa, Cerrahpaşa Faculty of Medicine, Department of Internal Medicine, İstanbul, Turkey

²Istanbul University-Cerrahpaşa, Cerrahpaşa Faculty of Medicine, Department of Internal Medicine, Division Rheumatology, İstanbul, Turkey

Abstract

A 23-year-old otherwise healthy female with family history of familial Mediterranean fever (FMF) in 2 siblings who are on colchicine presented with fever, pleuritis, pericarditis, peritonitis and multiple abscesses in the liver. Sampling from the liver abscess showed neutrophil predominance with no findings of granuloma, vasculitis, lymphoma or malignancy. Similarly, samples from peritoneum and pleural fluids are exudative and showed foamy histiocytes, polymorphonuclear leukocytes. No pathogens, including bacterial, viral and fungal agents, were grown in cultures. The inflammatory markers were very high, and despite multiple antibiotherapy, the clinical status and biochemistry picture did not improve. After excluding malignancy and infection, the picture was evaluated as an autoinflammatory disease and steroid treatment was started as anti-inflammatory therapy. Anti-interleukin 1 was added to the treatment of the patient who showed a dramatic radiological and clinical response to the steroid, and the steroid dose was reduced. Genomic DNA sample isolated from peripheral blood test showed homozygous MEFV m694v gene mutation diagnosing the patient with FMF.

Keywords: Aseptic abscesses, FMF, autoinflammation, steroid therapy, IL-1 antagonists

Öz

Yirmi üç yaşında kadın hasta bilinen bir hastalık öyküsü olmayıp 2 kardeşi ailevi Akdeniz ateşi (FMF) tanısı ile kolşisin kullanmaktadır. Hasta postpartum 5. ayda ateş, plevra, perikard, peritonda sıvı ve karaciğerde multipl apseler ile görüldü. Karaciğer biyopsisinde karaciğerdeki apselerde nötrofil ağırlıklı hücreler görüldü ve granülom, vaskülit, lenfoma ve epitelyal malignite açısından bulguya rastlanmadı ve apse iltihabi olarak rapor edildi. Benzer şekilde periton ve plevral sıvı örneklerinde eksuda ve köpüksü histiyositler, polimorfonükleer lökositler izlendi. Hastanın kültürlerinde bakteriyel, viral ve fungal ajanlar dahil olmak üzere hiçbir patojen üremedi. Hastanın enflamatuvar belirteçleri çok yüksekti ve çoklu antibiyoterapiye rağmen klinik durumu ve biyokimya tablosu düzelmedi. Hastanın yapılan tüm tetkiklerinde malignite ve enfeksiyon ekarte edildikten sonra mevcut tablo otoenflamatuvar hastalık olarak değerlendirildi ve anti-enflamatuvar tedavi olarak steroid tedavisi başlandı. Steroide radyolojik ve klinik olarak dramatik yanıt veren hastanın tedavisine anti-interlökin-1 ajanı eklendi ve steroid dozu azaltıldı. Periferik kandan izole edilen genomik DNA örneği MEFV m694v homozigot mutasyonu olarak sonuçlandı.

Anahtar Kelimeler: Aseptik apseler, FMF, otoenflamasyon, steroid tedavisi, IL-1 antagonistleri

Introduction

Aseptic abscesses are deep-seated, round, and sterile lesions that are rich in neutrophils. They do not respond to antibiotic therapy but do respond to steroid therapy. These lesions are not well-known.^[1] On closer examination, we can say that sterile inflammation is at the center of the disease pathogenesis. Although the majority of patients respond dramatically to steroids, approximately half of these patients relapse during the period when the steroid dose is reduced. In such cases, there are case-based studies in the literature that state tumor necrosis factor (TNF) alpha inhibitors

and interleukin-1 (IL-1) antagonists successfully keep the patient on remission, and protect them from the side effects of steroids.^[2,3]

Case Report

A 23-year-old otherwise healthy post-partum female with family history of familial Mediterranean fever (FMF) in 2 siblings who are on colchicine presented with fever, pleuritis, pericarditis, peritonitis and multiple abscesses in the liver (Figure 1). Prior to this, the patient had no FMF findings such as fever, abdominal pain, joint pain, chest pain, or rash.

Correspondence / İletişim:

Seyda Bilgin MD, İstanbul University-Cerrahpaşa, Cerrahpaşa Faculty of Medicine, Department of Internal Medicine, İstanbul, Turkey

Phone: +90 212 414 30 00 E-mail: seyda Bilgin@gmail.com ORCID ID: orcid.org/0000-0001-8068-506X

Received / Geliş Tarihi: 22.02.2023 Accepted / Kabul Tarihi: 21.03.2023

Cite this article as / Atıf: Bilgin S, Uğurlu S. FMF presented by aseptic abscesses. Ulus Romatol Derg 2023;15(3):167-170



©2023 The Author. Published by Galenos Publishing House on behalf of Turkish Society for Rheumatology.

This is an open access article under the Creative Commons Attribution-NonCommercial-NoDerivatives 4.0 (CC BY-NC-ND) International License.

©2023 Yazar. Türk Romatoloji Derneği adına Galenos Yayınevi tarafından yayımlanmıştır.

Creative Commons Atıf-GayriTicari-Türetilemez 4.0 (CC BY-NC-ND) Uluslararası Lisansı ile lisanslanmış, açık erişimli bir makaledir.



Sampling from the liver abscess showed neutrophil predominance with no findings of granuloma, vasculitis, lymphoma or malignancy. Similarly, exudate and foamy histiocytes, as well as polymorphonuclear leukocytes, were observed in samples from the peritoneum and pleural fluids. No pathogens, including tuberculosis, *salmonella*, *brucella*, viruses, and fungi, were grown in cultures. Parameters sent from the patient to exclude differential diagnoses, such as vasculitis, other connective tissue disorders, antiphospholipid syndrome, sarcoidosis, tuberculosis, neutrophil phagocytosis disorder, and macrophage activation syndrome, were negative (Table 1). Despite multiple antibiotic therapies, the patient's blood levels of procalcitonin, C-reactive protein, and sedimentary were very high, and the clinical status and

biochemistry picture did not improve. Once malignancy and infection were excluded, with the preliminary autoinflammation diagnosis, steroid treatment was continued at a dose of 60 mg/day after 3 days of 1 g steroid infusion. Most of the abscesses in the liver regressed, and the pleural and pericardial effusion resolved (Figure 2). With the steroid taper to 30 mg/day, anakinra 100 mg/day was added to the treatment. Gradually, the steroid dose was reduced to 5 mg/day. At the first month of this treatment, the patient's C-reactive protein and procalcitonin levels decreased (Table 2). Clinically, fever, pain, and fluid collection were not documented (Figure 3).

Based on all of this data, the patient was evaluated as having aseptic abscess syndrome (AAS) in the background

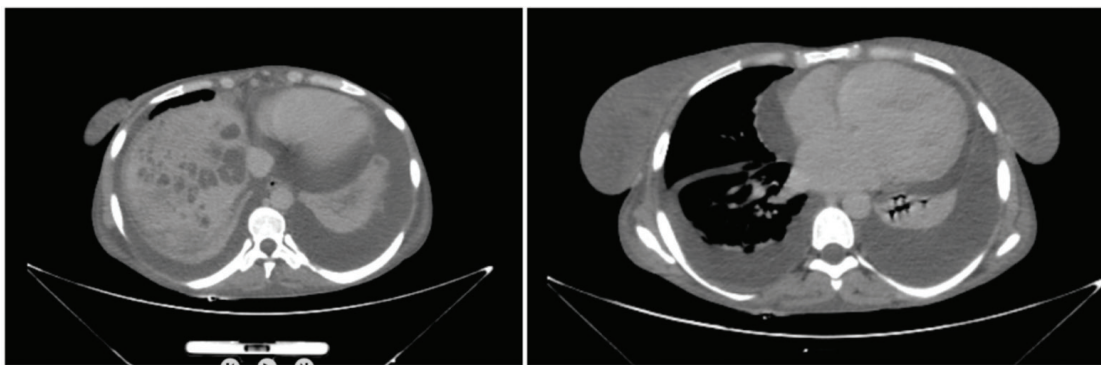


Figure 1. Before treatment CT images (bilateral pleural and pericardial effusions. Multiple hypodense abscess lesions in the liver)
CT: Computed tomography

Table 1. Some laboratory values of the patient at the time of diagnosis

Anti CCP: Negative	Anticardiolipin Ig M/G: Negative
Rheumatoid factor: Negative	Anti B2 Glycoprotein Ig M/G: Negative
ssA/ssB: Negative	Ig G1/G2/G3/G4 levels: High
ANA: Negative	Serum ACE level: Normal
Anti dsDNA: Negative	Pleural ADA level: Normal
SmRNP/anti sentromer/anti Scl 70: Negative	Serum Ig E level: Normal
p-ANCA, c-ANCA: Negative	Plasma NBT activity: Normal
<i>MEFV gene (Met694Val): Homozygous mutation</i>	

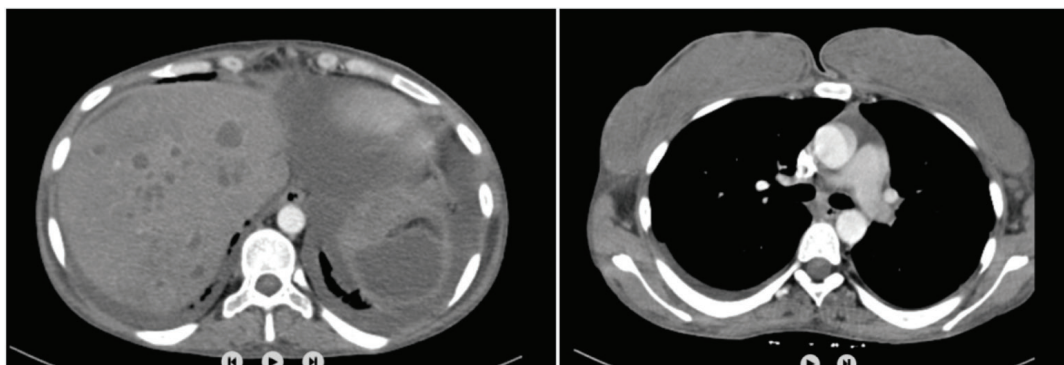


Figure 2. CT Images 2 weeks after starting steroid therapy (marked improvement in abscesses and effusions)
CT: Computed tomography

Table 2. Blood levels before and after treatment

Blood levels before treatment	Blood levels after 1 st month treatment
WBC/neutrophil: 22.400/19.100 μ L	WBC/neutrophil: 6800/4500 μ L
CRP: 248 mg/L	CRP: 12.16 mg/L
Ferritin: >2000 ng/mL	Ferritin: 359 ng/mL
Sedimentation rate: 89	Sedimentation rate: 14
Procalcitonin: 33.02 ng/mL	Procalcitonin: 0.398 ng/mL
Plasma lipid level: Normal	Plasma lipid level: Normal

CRP: C-reactive protein, WBC: White blood cell

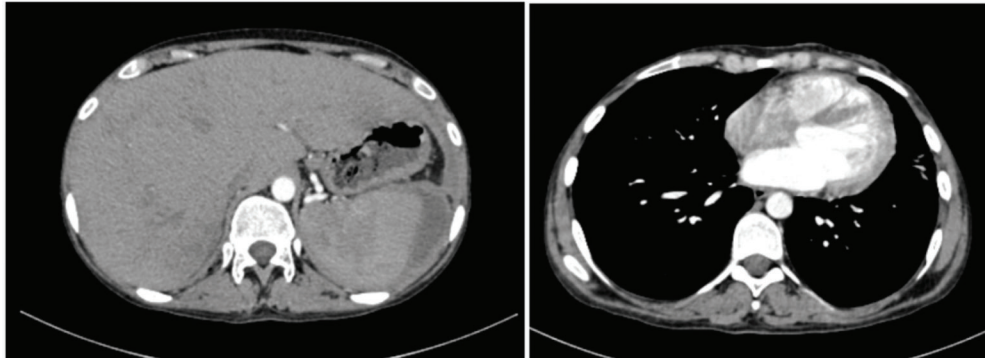


Figure 3. CT images at the end of first month (loss of abscess and effusions)
CT: Computed tomography

of an autoinflammatory disease which led to the diagnosis of FMF given the homozygous M694V mutation.

Discussion

AAS is a part of the large group of diseases that form the topic of neutrophilic diseases. It is a condition in which tissues are infiltrated by neutrophils and granuloma/vasculitis symptoms are not observed. No microorganisms can be produced in tissue and blood cultures, and antibiotic response is not obtained.^[4] AAS is characterized by typical features that include regional, systemic, clinical, and biological abnormalities. The clinical presentation usually includes fever (90%), weight loss (50%), and visceral pain (67%). Abscesses are usually found in the spleen (97%), followed by the liver (40%), abdominal lymph nodes (48%), and pancreas (7%). When looking at extra-abdominal locations, lung (17%), brain (7%), superficial lymph nodes, and skin were observed.^[2,5] Considering the blood analysis of the cases, it was seen that 70% had neutrophilic hyperleucocytosis, 95% had high C-reactive protein levels, and 47% had increased liver enzyme levels. Lesions are sterile in terms of bacteria, fungi, parasitosis, and viral agents. In addition, antinuclear antibody, rheumatoid factor, antineutrophilic cytoplasmic antibody, and anti-phospholipid antibody levels are also negative.^[4]

AAS is often associated with other diseases that need to be investigated and treated. For example, chronic

inflammatory bowel disease, relapsing polychondritis, spondyloarthropathy, neutrophilic dermatitis, monoclonal gammopathies, myelodysplasia, and sarcoidosis.^[6-10] The feature that makes this case interesting is that FMF has been detected as a result of this situation.

The specific criteria used in the diagnosis of AAS were radiologically demonstrated deep abscesses, neutrophilic cell dominance in the tissue samples taken from these abscesses, negative culture and serological results, no response to antibiotherapy and dramatic response to immunosuppressive therapy.^[11] AAS can occur in patients with FMF and is often misdiagnosed as infection. Failure to recognise this entity can lead to unnecessary morbidity and healthcare costs. AAS must be considered when patients develop deep abscesses that do not respond to conventional antibiotic therapy. The initial treatment of choice for AAS is high-dose intravenous glucocorticoids. Maintenance therapy should include a disease-modifying antirheumatic drug or biologically targeted agent or a combination of the two. The ideal regimen for maintenance therapy is still evolving. In patients placed on steroid maintenance therapy alone relapse occurred in some, but not all patients.^[12] Disease-modifying antirheumatic drugs (DMARDs) and biological targeted agents have been used as maintenance therapy. DMARDs that have been used to treat AAS include azathioprine, colchicine, cyclophosphamide, ciclosporin, methotrexate and mycophenolate mofetil. Biological targeted therapies that have been used include infliximab,

adalimumab, etanercept, anakinra, canakinumab and tocilizumab.

In the literature, it is observed that many treatment recommendations for AAS are based on clinical observations and experiences instead of randomized controlled clinical research results. Steroids are the cornerstone of treatment.^[12,13] For 2-4 weeks, 0.5 mg/kg/day can be started orally or intravenously, and the dose can be gradually reduced according to the clinical response. The prognosis for AAS is variable, and to date, death from AAS has not been reported. However, 60% of patients presented with relapses and required chronic immunosuppressive therapy.^[2,4] In addition to steroids, relapse cases can be treated with azathioprine (2-3 mg/kg), pulse cyclophosphamide, or methotrexate. In these cases, the use of anti-TNF-alpha or recombinant IL-1 receptor antagonists and anti-IL-1B monoclonal antibodies may be considered when relapsed.^[14,15]

IL-1B is an essential cytokine of the innate immune system. It is produced from myeloid cells as pro-IL1B and converted into its active form, IL-1B, with caspase 1 activity. The activation of caspase 1 depends on the inflammasome pathway. Uncontrolled activation in the Caspase 1 and IL-1B pathways leads to systemic and multi-organ sterile inflammation. In autoinflammatory diseases, fever, arthritis, serositis, rash, and sterile abscesses are observed, while neutrophils and high acute phase reactants are used to monitor treatment response. In summary, the uncontrolled activation of the innate immune response can manifest itself with a clinical picture such as aseptic abscess, fever, and serositis, as in our case (inflammasome formation → caspase 1 activation → IL-1B release). Successful treatment modalities aimed at suppressing this pathway have been observed, where IL-1B plays a crucial role in the pathophysiology of aseptic abscess.

Conclusion

In conclusion, IL-1B blockade is a good treatment option in cases of AAS that require a high steroid dose and are not well controlled, as in our case.^[3]

Ethics

Informed Consent: Informed consent was obtained.

Peer-review: Externally and internally peer-reviewed.

Authorship Contributions

Concept: S.B., S.U., Design: S.B., S.U., Analysis or Interpretation: S.B., S.U., Literature Search: S.B., Writing: S.B.

Conflict of Interest: No conflict of interest was declared by the authors.

Financial Disclosure: The authors declared that this study received no financial support.

References

1. Yildiz H, Munting A, Komuta M, Danse E, Lefebvre C. Aseptic lung and liver abscesses: a diagnostic challenge. *Acta Clin Belg* 2017;72:259-63.
2. Andre MF, Piette JC, Kemeny JL, et al. Aseptic abscesses: a study of 30 patients with or without inflammatory bowel disease and review of the literature. *Medicine (Baltimore)* 2007;86:145-61.
3. Bardy A, Guettrot-Imbert G, Aumaître O, André MF. Efficacy of IL-1β blockade in refractory aseptic abscesses syndrome. *Mod Rheumatol* 2014;24:217-9.
4. André M, Aumaitre O. Aseptic abscesses syndrome. *Rev Med Interne* 2011;32:678-88.
5. Szwebel TA, Casadevall M, Chosidow O, et al. Atypical recurrent aseptic cutaneous abscesses as the presenting manifestation of Crohn's disease. *Rev Med Interne* 2010;31:705-8.
6. Kémény JL, André M, Charlotte F, Piette JC, Amouroux J, Aumaître O. Abscesses aseptiques chez huit patients atteints d'une maladie inflammatoire cryptogénétique intestinale [Aseptic abscesses in eight patients with cryptogenic inflammatory bowel disease]. *Ann Pathol* 1999;19:294-8.
7. Zakout R, Fonseca M, Santos JM, et al. Multiple aseptic liver abscesses as the initial manifestation of Crohn's disease: report of a case. *Dis Colon Rectum* 2009;52:343-5.
8. Sakharpe AK, Sakharpe AK, Mirmanesh M, et al. A case and review of aseptic liver abscess in Crohn's disease. *Int J Colorectal Dis* 2016;31:787-8.
9. André M, Piette JC, Francès C, Aumaître O. Dermatoses neutrophiliques et abcès aseptiques: deux expressions cliniques d'une même entité [Neutrophilic dermatoses and aseptic abscesses: two sides of the same entity]. *Rev Med Interne* 2005;26:5-7.
10. Tokgoz S, Ogmegul A, Mutluer M, Kivrak AS, Ustun ME. Cerebral abscesses in Behcet's disease: a case report. *Turk Neurosurg* 2012;22:116-8.
11. Maeshima K, Ishii K, Inoue M, Himeno K, Seike M. Behçet's disease complicated by multiple aseptic abscesses of the liver and spleen. *World J Gastroenterol* 2013;19:3165-8.
12. André M, Piette JC, Aumaître O. Corticosteroid-sensitive aseptic abscess associated with inflammatory bowel disease. An emerging syndrome. *Presse Med* 2001;30:1767-8.
13. Wallach D, Vignon-Pennamen MD. From acute febrile neutrophilic dermatosis to neutrophilic disease: forty years of clinical research. *J Am Acad Dermatol* 2006;55:1066-71.
14. Bardy A, Guettrot-Imbert G, Aumaître O, André MF. Efficacy of IL-1β blockade in refractory aseptic abscesses syndrome. *Mod Rheumatol* 2014;24:217-9.
15. Ito T, Sato N, Yamazaki H, Koike T, Emura I, Saeki T. A case of aseptic abscesses syndrome treated with corticosteroids and TNF-alpha blockade. *Mod Rheumatol* 2013;23:195-9.