

# A case that developed acute generalized exanthematous pustulosis after hydroxychloroquine use and did not follow the ordinary healing process despite drug discontinuation

Hidroksiklorokin kullanımından sonra akut generalize ekzantematöz püstüloz gelişen ve ilaç kesilmesine rağmen olağan iyileşme sürecini takip etmeyen bir olgu

• Melih Kızıltepe<sup>1</sup>, • Emel Oğuz Kökoğlu<sup>1</sup>, • Yasemin Özden Eldemir<sup>1</sup>, • Senem Şaş<sup>2</sup>, • Abdurrahman Soner Şenel<sup>1</sup>

<sup>1</sup>Erciyes University Faculty of Medicine, Department of Internal Medicine, Division of Rheumatology, Kayseri, Turkey

<sup>2</sup>Erciyes University Faculty of Medicine, Department of Physical Medicine and Rehabilitation, Division of Rheumatology, Kayseri, Turkey

## Abstract

Acute generalized exanthematous pustulosis is a disease that usually presents with sudden onset and widespread rash over the body. It is a condition characterized by non-follicular, sterile pustules that develop acutely with a base of edematous erythema. Acute generalized exanthematous pustulosis is usually drug-related, and hydroxychloroquine, an antimalarial drug frequently used in rheumatology practice, is one of the rare causes of acute generalized exanthematous pustulosis. Generally, spontaneous regression is expected after drug discontinuation. A sixty-year-old female patient developed acute generalized exanthematous pustulosis while receiving hydroxychloroquine. Despite drug discontinuation and steroid treatment, the lesions were persistent. The patient was treated with methotrexate and the lesions had resolved. It is aimed to raise awareness of the rare hydroxychloroquine-acute generalized exanthematous pustulosis relationship and its treatment with methotrexate by presenting this case.

**Keywords:** Acute generalized exanthematous pustulosis, case report, hydroxychloroquine, methotrexate

## Öz

Akut generalize ekzantematöz püstüloz, genellikle ani başlangıçlı ve tüm vücutta yaygın döküntülerle seyreden bir hastalıktır. Ödemli eritem zemininde akut gelişen, steril püstüllerle karakterize bir durumdur. Genellikle ilaca bağlıdır ve romatoloji pratiğinde sıklıkla kullanılan hidroksiklorokin, akut generalize ekzantematöz püstülozun nadir nedenlerinden biridir. Genellikle ilaç kesildikten sonra spontan gerileme beklenir. Altmış yaşında bir kadın hastada hidroksiklorokin tedavisi sırasında akut generalize ekzantematöz püstüloz gelişti. İlaç kesilmesine ve steroid tedavisine rağmen lezyonlar dirençliydi. Bunun üzerine methotrexate başlanan hastanın tedavisiyle lezyonları tamamen geriledi. Bu olgu sunumu ile nadir görülen hidroksiklorokin-akut generalize ekzantematöz püstüloz ilişkisi ve metotreksat ile tedavisi konusunda farkındalık yaratmak amaçlanmıştır.

**Anahtar Kelimeler:** Akut generalize ekzantematöz püstüloz, olgu sunumu, hidroksiklorokin, methotrexate

## Introduction

Acute generalized exanthematous pustulosis (AGEP) is a disease that usually presents with sudden onset and widespread rash over the body. Mucosal or internal organs are not expected to be affected but can be involved in severe case.<sup>[1]</sup> Intertriginous areas are the most involved.

Most common two reasons are medication (beta-lactam antibiotics) and viral infections.<sup>[2]</sup> The incidence of AGEP is estimated to be one to five cases per million people per year. Only 18% of these are non-antibiotic drugs.<sup>[3]</sup> Hydroxychloroquine (HCQ) is an antimalarial drug used in many rheumatological diseases due to its anti-inflammatory and immunomodulatory effects. Although well-known

## Correspondence / İletişim:

Melih Kızıltepe MD, Erciyes University Faculty of Medicine, Department of Internal Medicine, Division of Rheumatology, Kayseri, Turkey

Phone: +90 534 876 20 99 E-mail: melih38kiziltepe@hotmail.com ORCID ID: orcid.org/0000-0001-6100-2024

Received / Geliş Tarihi: 22.02.2023 Accepted / Kabul Tarihi: 10.06.2023

**Cite this article as / Atıf:** Kızıltepe M, Oğuz Kökoğlu E, Eldemir YÖ, Şaş S, Şenel AS. A case that developed acute generalized exanthematous pustulosis after hydroxychloroquine use and did not follow the ordinary healing process despite drug discontinuation. Ulus Romatol Derg 2023;15(3):171-174



©2023 The Author. Published by Galenos Publishing House on behalf of Turkish Society for Rheumatology.

This is an open access article under the Creative Commons Attribution-NonCommercial-NoDerivatives 4.0 (CC BY-NC-ND) International License.

©2023 Yazar. Türk Romatoloji Derneği adına Galenos Yayınevi tarafından yayımlanmıştır.

Creative Commons Atıf-GayriTicari-Türetilemez 4.0 (CC BY-NC-ND) Uluslararası Lisansı ile lisanslanmış, açık erişimli bir makaledir.



side effects include retinopathy, hypoglycemia, and skin pigmentation, it is generally well tolerated by patients and is one of the rare drugs that cause AGEP.<sup>[4]</sup> AGEP is more common in women.<sup>[5]</sup> The duration of the latent period may vary depending on the type of drug used. Fever may accompany the rash in AGEP.

Histopathological examination typically reveals spongiform sub-corneal and/or intraepidermal pustules, and edema in the papillary dermis.<sup>[6]</sup> In the laboratory, especially leukocytosis with neutrophil dominance is observed. Spontaneous regression is seen with discontinuation of the agent and supportive treatment, which is the mainstay of treatment.

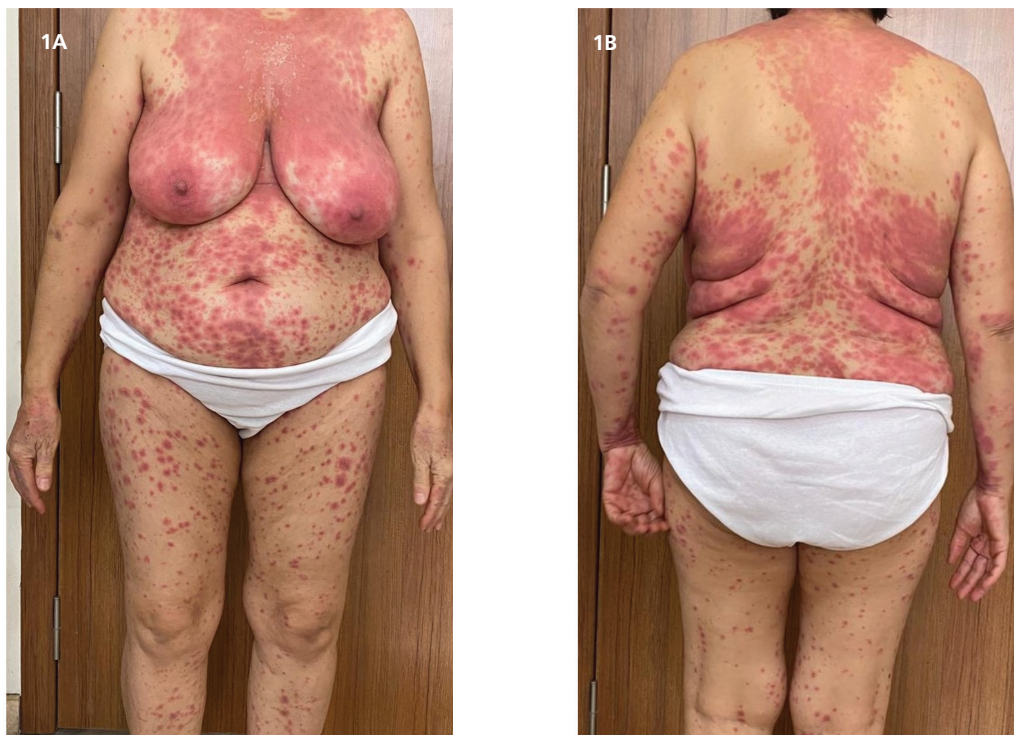During the healing period, desquamation occurs in the affected areas. HCQ has an exceptionally long half-life; therefore, AGEP caused by HCQ may not follow the typical rapid recovery time.<sup>[7]</sup>

Here, we present a case of AGEP who developed AGEP after HCQ use and did not follow the usual recovery process after discontinuing the drug.

### Case Report

A sixty-year-old female patient with joint complaints for six months was followed by our rheumatology outpatient clinic. Her rheumatological examination showed dry mouth and joint tenderness, especially in the small joints. The ophthalmologist also confirmed dry eye with the Schirmer

test. Anti-nuclear antibody of 1/160 titer, and anti-SSA (++) were found. Connective tissue disease/Sjögren's syndrome was considered as a preliminary diagnosis hence HCQ and prednisolone were started. Three weeks later, the patient presented with a widespread rash, mainly on the trunk. Pustular lesions and erythematous plaques were accompanied by desquamation (Figure 1A, 1B). Her fever was subfebrile, the rest of the physical exam was normal. She did not have psoriasis in her past medical and family history. Remarkable labs included a hemoglobin level of 10.4 g/dL, leukocyte of 20,000/mm<sup>3</sup> (81% neutrophil), Erythrocyte sedimentation rate of 5 mm/s, C-reactive protein (CRP) of 62.4 mg/L, and normal rheumatoid factor, anti-cyclic citrulline peptide levels. Cultures of peripheral blood, urine and pustules remained negative. A biopsy was performed from the lesions and reported as "subcorneal pustular dermatosis, findings consistent with AGEP" (Figures 2A, 2B). AGEP was considered clinically and histopathologically in the patient who consulted dermatology. HCQ was discontinued, and 64 milligrams (mg) of methylprednisolone, antihistamine, and topical moisturizer were started. Methylprednisolone dose was reduced to 48 mg after ten days. Due to the recovery of the lesions, the dose of methylprednisolone was reduced by 8 mg per week. Although it responded well to high-dose methylprednisolone, the lesions were resistant to 16 mg of methylprednisolone treatment. Upon this, the patient was given methotrexate (MTX) 15 mg/week. Improvement of



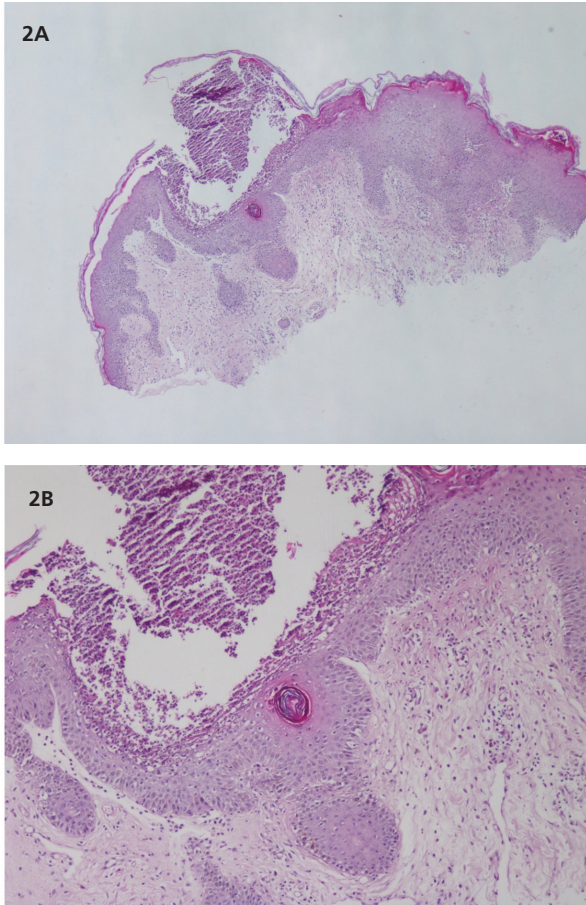
**Figure 1A, 1B.** Widespread pustular lesions and erythematous plaques on the trunk



cutaneous findings, symptoms, and laboratory parameters including neutrophilia were evident within four weeks of starting MTX (Figure 3). Steroid treatment was gradually tapered and stopped at six weeks. After ten weeks of MTX administration, the lesions resolved. Three months after initiation of MTX at 15 mg/week, tapering by 7.5 mg/week was attempted and the treatment was terminated at four months.

## Discussion

Although AGEF was previously described as a form of pustular psoriasis, it was first described in 1980 by Beylot et al.<sup>[8]</sup> and defined as a clinical picture different from psoriasis. In subsequent studies, the characteristic features of the disease were determined as intraepidermal or subcorneal pustules, dermal edema, perivascular eosinophil/neutrophil predominance, and fever. Although the cause is unknown, acute phase reactant elevation is sometimes observed. In our case, there were neutrophil-dominated white blood cell elevation, CRP elevation, fever, recent suspected drug use, and sudden onset pustular rashes. The pathology result confirmed the diagnosis.

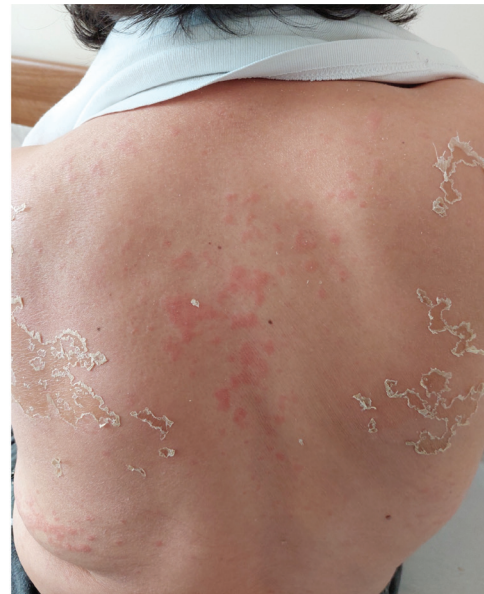

**Figure 2A, 2B.** Subcorneal pustular dermatosis and perivascular inflammatory reaction

AGEF is a rare disease, but in a 2007 study, the development rate of AGEF due to HCQ was found to be 7%.<sup>[9]</sup> In the literature, a case series from 2022 of 297 patients, reported a rate of 12.8% for AGEF due to HCQ.<sup>[5]</sup> The increase in this rate in current studies, especially in 2022, may be due to the everyday use of HCQ in treating COVID-19.

The duration of clinical development in AGEF may differ according to the drug and may last for hours, days, or weeks. In case of antibiotic related AGEF, the most common cause, this period is 48 hours, but it may take 2-4 weeks in HCQ. In addition, AGEF usually regresses within two weeks after discontinuation of the drug, although after HCQ, resistance to systemic therapy and delayed response have been observed. These may be due to the metabolic characteristics of HCQ, such as the half-life of 40-50 days and immune dysregulation of the concomitant disease.<sup>[9]</sup> Non-follicular eruptions on an erythematous surface spreading on a large scale are clinical features. Fever accompanies most of the patients (64.3%). Oral mucosal involvement is rare and generally seen in severe cases.<sup>[1]</sup> In our case, there was only skin involvement and fever without involvement of the oral mucosa. It also had the characteristics of HCQ in terms of duration.

There is no specific method for the treatment of AGEF. The most critical step is the elimination of the agent, the illness should respond in a few days. AGEF is generally self-limited and has a favorable prognosis. However, sometimes it can be severe enough to require hospitalization. Death was reported in a case of AGEF due to HCQ use. Except for drug discontinuation, topical corticosteroids benefit patients with itching and inflammation.<sup>[1]</sup> In severe or



**Figure 3.** The erythematous eruption and pustules were resolved, followed by desquamation

resistant cases, systemic corticosteroids, and cyclosporine may help accelerate disease clearance.<sup>[1,4]</sup> Also, treatment with systemic steroids was associated with decreased hospital stays in patients with AGEP.<sup>[10]</sup> Despite systemic steroid treatment, our case did not follow the ordinary healing process and MTX (15 mg/week) helped with resolution within four weeks. The mechanism of action of MTX correlates with the pathophysiology of AGEP which is a neutrophilic inflammatory response associated with T cells. MTX is generally known as an antimetabolite that inhibits dihydrofolate reductase. It is an anti-inflammatory and immunosuppressive agent that inhibits lymphocytes. The reduction of neutrophil release is another effect.<sup>[11]</sup>

Although it has been used frequently in rheumatology practice, AGEP due to HCQ is rare in the literature. Due to the causative drug or the underlying disease, the latent period may take longer and may be resistant to steroid therapy.

To our knowledge, only one case of AGEP treated with MTX has been previously reported. There is very limited data about this subject.<sup>[11]</sup> Thus, our report shows that MTX can also be considered as a treatment option in steroid resistant AGEP.

#### **Ethics**

**Informed Consent:** Informed consent was obtained.

**Peer-review:** Externally and internally peer-reviewed.

#### **Authorship Contributions**

Concept: M.K., Design: M.K., Data Collection or Processing: A.S.Ş., Analysis or Interpretation: M.K., Literature Search: M.K., E.O.K., Y.Ö.E., S.Ş., Critical Review: M.K., E.O.K., Y.Ö.E., S.Ş., A.S.Ş., Writing: M.K.

**Conflict of Interest:** No conflict of interest was declared by the authors.

**Financial Disclosure:** The authors declared that this study received no financial support.

#### **References**

1. Szatkowski J, Schwartz RA. Acute generalized exanthematous pustulosis (AGEP): A review and update. *J Am Acad Dermatol* 2015;73:843-8.
2. Fernando SL. Acute generalised exanthematous pustulosis. *Australas J Dermatol* 2012;53:87-92.
3. Bailey K, McKee D, Wismer J, Shear N. Acute generalized exanthematous pustulosis induced by hydroxychloroquine: first case report in Canada and review of the literature. *J Cutan Med Surg* 2013;17:414-8.
4. Bal M, Kartal SP, Gönül M, Han Ü, Çağın M. Efficacy of Cyclosporine in Hydroxychloroquine induced steroid resistant acute generalized exanthematous pustulosis. *Dermatoz* 2019;10:115-9.
5. Vallejo-Yagüe E, De la Torre AM, Mohamad OS, Sabu S, Burden AM. Drug triggers and clinic of acute generalized exanthematous pustulosis (AGEP) : A literature case series of 297 patients. *J Clin Med* 2022;11:397.
6. Kardaun SH, Kuiper H, Fidler V, Jonkman MF. The histopathological spectrum of acute generalized exanthematous pustulosis (AGEP) and its differentiation from generalized pustular psoriasis. *J Cutan Pathol* 2010;37:1220-9.
7. Pearson KC, Morrell DS, Runge SR, Jolly P. Prolonged pustular eruption from hydroxychloroquine: an unusual case of acute generalized exanthematous pustulosis. *Cutis* 2016;97:212-6.
8. Beylot C, Bioulac P, Doutre MS. Pustuloses exanthématiques aiguës généralisées. A propos de 4 cas [Acute generalized exanthematic pustuloses (four cases) (author's transl)]. *Ann Dermatol Venereol* 1980;107:37-48.
9. Sidoroff A, Dunant A, Viboud C, et al. Risk factors for acute generalized exanthematous pustulosis (AGEP)-results of a multinational case-control study (EuroSCAR). *Br J Dermatol* 2007;157:989-96.
10. Oh DAQ, Yeo YW, Choo KJL, Pang SM, Oh CC, Lee HY. Acute generalized exanthematous pustulosis: Epidemiology, clinical course, and treatment outcomes of patients treated in an Asian academic medical center. *JAAD Int* 2021;3:1-6.
11. Djawad K. Steroid-resistant acute generalized exanthematous pustulosis mimicking generalized pustular psoriasis successfully treated by Methotrexate. *The Journal of the Portuguese Society of Dermatology and Venereology* 2021;79:257-60.